

Diffuse high-grade gliomas with H3 K27M mutations carry a dismal prognosis independent of tumor location

Michael Karremann,[†] Gerrit H. Gielen,[†] Marion Hoffmann, Maria Wiese, Niclas Colditz, Monika Warmuth-Metz, Brigitte Bison, Alexander Claviez, Dannis G. van Vuurden, André O. von Bueren, Marco Gessi, Ingrid Kühnle, Volkmar H. Hans, Martin Benesch, Dominik Sturm, Rolf-Dieter Kortmann, Andreas Waha, Torsten Pietsch, and Christof M. Kramm

Department of Pediatric and Adolescent Medicine, University Medical Center Mannheim, Medical Faculty Mannheim, Heidelberg University, Mannheim, Germany (M.K.); Department of Neuropathology, University Hospital Bonn, Bonn, Germany (G.H.G., M.G., A.W., T.P.); Division of Pediatric Hematology and Oncology, Department of Child and Adolescent Health, University Medical Center Goettingen, Goettingen, Germany (M.H., M.W., N.C., A.O.v.B., I.K., C.M.K.); Department of Neuroradiology, University Hospital Wuerzburg, Wuerzburg, Germany (M.W.-M., B.B.); Department of Pediatrics, Schleswig-Holstein Medical University in Kiel, Kiel, Germany (A.C.); Department of Pediatrics, Division of Oncology/Hematology, VU University Medical Center, Amsterdam, Netherlands (D.G.v.V.); Department of Pediatrics and Adolescent Medicine, Division of Pediatric Hematology and Oncology, University Hospital of Geneva, Geneva, Switzerland (A.O.v.B.); Department of Pathology, Universitätsmedizin Greifswald, Greifswald, Germany (V.H.H.); Institute of Neuropathology, Evangelisches Krankenhaus Bielefeld, Bielefeld, Germany (V.H.H.); Division of Pediatric Hematology and Oncology, Department of Pediatrics and Adolescent Medicine, Medical University Graz, Graz, Austria (M.B.); Division of Pediatric Neurooncology, German Cancer Research Center Heidelberg, Heidelberg, Germany (D.S.); Department of Radiotherapy and Radiation Oncology, University of Leipzig Medical Center, Leipzig, Germany (R-D.K.)

Corresponding Author: Gerrit H. Gielen, M.D., Institute of Neuropathology, University Hospital Bonn, Sigmund-Freud-Str. 25, 53105 Bonn, Germany (Gerrit.Gielen@ukbonn.de).

[†]These authors contributed equally to this work.

Abstract

Background. The novel entity of “diffuse midline glioma, H3 K27M-mutant” has been defined in the 2016 revision of the World Health Organization (WHO) classification of tumors of the central nervous system (CNS). Tumors of this entity arise in CNS midline structures of predominantly pediatric patients and are associated with an overall dismal prognosis. They are defined by K27M mutations in *H3F3A* or *HIST1H3B/C*, encoding for histone 3 variants H3.3 and H3.1, respectively, which are considered hallmark events driving gliomagenesis.

Methods. Here, we characterized 85 centrally reviewed diffuse gliomas on midline locations enrolled in the nationwide pediatric German HIT-HGG registry regarding tumor site, histone 3 mutational status, WHO grade, age, sex, and extent of tumor resection.

Results. We found 56 H3.3 K27M-mutant tumors (66%), 6 H3.1 K27M-mutant tumors (7%), and 23 H3-wildtype tumors (27%). H3 K27M-mutant gliomas shared an aggressive clinical course independent of their anatomic location. Multivariate regression analysis confirmed the significant impact of the H3 K27M mutation as the only independent parameter predictive of overall survival ($P = 0.009$). In H3 K27M-mutant tumors, neither anatomic midline location nor histopathological grading nor extent of tumor resection had an influence on survival.

Conclusion. These results substantiate the clinical significance of considering diffuse midline glioma, H3 K27M-mutant, as a distinct entity corresponding to WHO grade IV, carrying a universally fatal prognosis.

Key words

children | diffuse midline glioma | high-grade glioma | histone H3 | K27M mutation

Importance of the study

The 2016 revision of the WHO classification of tumors of the CNS introduces “diffuse midline glioma, H3 K27M-mutant” as a novel entity defined by K27M mutations in the histone genes *H3F3A* and *HIST1H3B/C* and corresponding to WHO grade IV, independent of histological signs of anaplasia. Previous reports have suggested a prognostic impact of H3 K27 mutational status for thalamic tumors and/or diffuse intrinsic pontine gliomas revealing a particularly dismal

prognosis. In the present study, we demonstrate that H3 K27M-mutant gliomas share an invariably fatal clinical course independent of anatomic midline location, histopathological grading, and extent of tumor resection by investigation of 85 diffuse midline gliomas enrolled in the nationwide pediatric German HIT-HGG registry with comprehensive clinical, pathological, and radiological data from 5 consecutive clinical trials.

The extensive molecular characterization of brain tumors over recent years has revolutionized our current understanding of the underlying biology in many of these tumor entities.¹ In the recent revision of the World Health Organization (WHO) classification of tumors of the CNS, the principle of an integrated diagnosis was introduced with the combination of histological and molecular features, exemplified in the novel entity “diffuse midline glioma, H3 K27M-mutant.”² This tumor entity is described as “an infiltrative midline high-grade glioma with predominantly astrocytic differentiation and a K27M mutation in either *H3F3A* or *HIST1H3B/C*,” typically affecting children and young adults.³ Tumors mainly arise within thalamic, pontine, and spinal localization, all of those representing challenging sites for surgical treatment.

K27M mutations in *H3F3A* or *HIST1H3B/C*, encoding for histone 3 variants H3.3 and H3.1, respectively, lead to the amino acid substitution of lysine for methionine in position 27 of the histone H3 tail and a subsequent loss of trimethylation at H3 lysine 27 by inhibition of the Polycomb repressive complex 2.^{4,5} The resulting alterations in gene expression patterns have been suggested to impede physiological differentiation and to drive gliomagenesis.^{4,6,7} Because of its overall adverse prognosis, H3 K27M-mutant diffuse midline glioma is defined to correspond to WHO grade IV, even if tumor histology does not fulfill all defining criteria of a high-grade glioma (HGG), such as high mitotic activity, microvascular proliferation, and/or necrosis. Recent reports investigating thalamic tumors and/or diffuse intrinsic pontine gliomas (DIPGs) have suggested a prognostic impact of H3 K27 mutational status.^{8–12} While statistical analyses in DIPG are often limited by the lack of a significant proportion of H3 K27-wildtype tumors, relevant patient numbers with well-annotated clinical data are often missing for H3 K27M-mutant thalamic and spinal pediatric HGG.

Here, we retrospectively identified 85 pediatric diffuse midline gliomas from the HIT-HGG database of the Society of Pediatric Oncology and Hematology (Gesellschaft für Pädiatrische Onkologie und Hämatologie [GPOH]), from which comprehensive clinical, pathological, and radiological data from 5 consecutive clinical trials in pediatric HGG/DIPG are available. The presented results from analyzing this series for H3 K27 mutational status, anatomic tumor location, age, sex, and extent of tumor resection underline the importance of considering H3 K27M-mutant diffuse midline gliomas a distinct biological tumor entity.

Patients and Methods

Patients' Characteristics and Inclusion/Exclusion Criteria

Patient data were obtained from the HIT-HGG database of the GPOH in Germany, Austria, and Switzerland. The HIT-HGG database contains clinical data of patients enrolled in the various HIT-GBM trials^{13–16} and the ongoing HIT-HGG-2007 trial (Eudra-CT 2007-010128-42, ISRCTN19852453). Very young children <3 years of age predominantly treated according to the HIT-SKK regimen¹⁷ were also prospectively registered as observational patients within the different trials. All studies were reviewed by the institutional review boards of all participating oncological centers and informed consent for data storage and statistical analyses was given by all patients and/or their parents at the time of enrollment in the various trials in accordance with the Declaration of Helsinki.

For the present study, the following inclusion criteria were defined:

- (A) Central neuropathological re-review (T.P., G.H.G., the German Brain Tumor Reference Center, Department of Neuropathology, Bonn, Germany) of a histopathological diagnosis of a diffuse midline glioma as defined by WHO classification,² showing features either of a diffuse midline glioma, H3 K27M-mutant, WHO grade IV (DMGIV), a midline glioblastoma WHO grade IV (GBMIV), or a midline anaplastic astrocytoma WHO grade III (AAIII). In DIPG, grade II gliomas were also included.
- (B) Central neuroradiological review (M.W-M., B.B., Department of Neuroradiology, Wuerzburg, Germany) in tumors affecting the pons. In these tumors, a DIPG was defined by tumor infiltration of the pons by more than 50% of the total diameter in a patient with “classical” brainstem symptoms (eg, cranial nerve deficit or long tract signs, ataxia, a combination of any two).
- (C) Molecular genetic characterization of *H3F3A* and *HIST1H3B* showing either H3 K27M mutation or H3 K27-wildtype status.
- (D) Patients 0–18 years of age at time of diagnosis.

Treatment Protocols

In each of the various clinical trials, best feasible tumor resection was recommended before starting chemo- and/

or radiotherapy. The extent of tumor resection was determined on the basis of early postsurgical imaging and/or the neurosurgical report. Gross total tumor resection was defined as 100% macroscopic removal of the tumor mass. Subtotal tumor resection was defined as removal of 90%–99% of the tumor mass, partial tumor resection as 50%–89% resection. Removal of <50% of tumor mass was defined as non-debulking tumor resection including tumor biopsies. Pediatric patients ≥ 3 years of age were enrolled in the various HIT-GBM/HIT-HGG trials, including standard fractionated radiotherapy and adjuvant chemotherapy as described previously.¹⁸ Children younger than 3 years were primarily treated with surgery and chemotherapy alone following the HIT-SKK treatment recommendation for infant patients with brain tumors except for intrathecal chemotherapy, which was usually omitted.¹⁷

Neuropathological Evaluation

Routine neuropathological evaluation of the formalin-fixed/paraffin-embedded pediatric HGG tumor samples included hematoxylin and eosin and reticulin fiber staining as well as immunohistochemical analysis performed on a Ventana Benchmark XT Immunostainer (Roche) with antibodies against glial fibrillary acidic protein (Dako), microtubule-associated protein 2 (Sigma), p53 protein (Dako), alpha thalassemia/mental retardation syndrome X-linked protein (ATRX; Sigma), and Ki67 (Mib-1; Dako). In addition, histone 3 K27 mutational status was determined by immunohistochemistry with antibodies against mutant H3 K27M (Millipore) and trimethylated H3 K27 (Cell Signaling), and/or by pyrosequencing of position K27 of *H3F3A* and *HIST1H3B*, respectively.¹⁹ Nuclear accumulation of p53 protein was determined semiquantitatively, and a strong positive staining in more than 10% of tumor cell nuclei was considered significantly accumulated and suggestive for an underlying *TP53* missense mutation.²⁰

Statistical Analysis

Statistical analysis was retrospectively performed using IBM SPSS Statistics v23.

Tumors were defined by histone H3 phenotype including H3.3/H3.1 K27-wildtype, H3.3 K27M mutation, and H3.1 K27M mutation. The anatomic subgroups “DIPG,” “thalamic region” (including thalamic and basal ganglia HGG), “spinal cord,” and “other midline HGG” (including tumors arising from the medulla, tegmentum, and tectum, as well as pontine HGG that did not meet the criteria of a DIPG by central neuroradiological review) were defined by typical anatomic landmarks.

Subgroups were compared for children ≥ 3 years of age at diagnosis by the following parameters: age at diagnosis (y); sex (male/female); duration of symptoms before diagnosis (mo), and metastases during course of the disease (yes/no). Histopathological criteria were WHO grading (II, III, and IV), ATRX loss of expression, and nuclear accumulation of p53 protein. Therapeutic procedures were defined as extent of resection (gross total = 100%, subtotal = 90%–99%, partial = 50%–89%, non-debulking/biopsy $\leq 50\%$ resection of

initial tumor volume), application of radiotherapy (yes/no), and chemotherapy (yes/no).

A 2-sided chi-square test was performed to determine significant differences between subgroups regarding sex, metastases, genetic aberrations, WHO grading, ATRX loss, and the application of radiotherapy and chemotherapy, as well as the extent of resection. Differences in age distribution and duration of symptoms were evaluated by the Mann–Whitney *U*-test. The prognostic significance for overall survival (OS) was analyzed for “tumor site,” “WHO grading,” “sex,” “H3 K27 phenotype,” “tumor resection,” and “very young age (<3 years of age)” as defined above by univariate Kaplan–Meier analysis and log-rank testing, as well as multivariate Cox regression analysis.

For all statistical analyses, $P < 0.05$ was considered statistically significant.

Results

Patients

Eighty-five pediatric diffuse gliomas located in the midline with available H3 K27 mutation status and subsequent central neuropathological re-review were identified as diffuse midline gliomas. Eight children <3 years of age were studied separately due to their different treatment and supposedly better survival. The remaining 77 non-infant diffuse midline gliomas included 56 H3.3 K27M-mutant tumors (73%), 5 H3.1 K27M-mutant tumors (6%), and 16 H3 K27-wildtype tumors (21%). Details regarding clinical data, tumor characteristics, and patient survival are given in [Table 1](#) and Supplementary Table S1. The H3 K27M-mutant diffuse midline gliomas (DMGIV) included 26 DIPGs with classical radiological features confirmed by central neuroradiological review. The remaining nonpontine DMGIV were located within the thalamus ($n = 24$), spinal cord ($n = 6$), and other midline (brainstem) structures ($n = 5$) ([Fig. 1](#)). The mean age at diagnosis in H3 K27M-mutant DMGIV was 10.2 ± 3.8 years and comparable to H3 K27-wildtype diffuse midline glioma (11.4 ± 4.4 y). Age varied observably, albeit not significantly by tumor site. Mean age at diagnosis was 9.1 ± 4.0 years in DIPG, 11.2 ± 3.8 years in thalamic, 11.9 ± 1.7 years in spinal, and 9.2 ± 3.2 years in other midline DMGIV (differences not statistically significant; Supplementary Figure S1). H3 K27M-mutant and wildtype tumors also presented with a similarly short mean history of 2.0 ± 2.6 months and 2.3 ± 2.3 months, respectively, and with equal sex distribution. All H3 K27-wildtype tumors presented with localized disease, whereas initial metastases were detected in 4 of 61 patients (6.6%) with K27M-mutant midline gliomas (not significant). Metastasis during the course of the disease occurred in 3 of 20 patients with H3 wildtype glioma compared with 15 of 58 H3 K27M-mutant tumors (not significant).

There was no difference in sex or duration of symptoms between patients with H3.3 K27M-mutant and H3.1 K27M-mutant tumors. Two H3.1 K27M-mutant gliomas occurred outside the pons in thalamic regions. Patients with H3.1 K27M-mutant tumors were significantly younger

Table 1 Clinical characteristics and survival of 77 pediatric patients ≥ 3 years of age at diagnosis with diffuse midline glioma from the HIT-HGG registry

	Thalamus			DIPG			Spine			Other Midline Structures		
	H3 Wildtype	H3 K27M	<i>P</i>	H3 Wildtype	H3 K27M	<i>P</i>	H3 Wildtype	H3 K27M	<i>P</i>	H3 Wildtype	H3 K27M	<i>P</i>
Number (H3.3/H3.1)	8	24 (22/2)	–	1	26 (23/3)	–	5	6 (6/0)	–	2	5 (5/0)	–
Epidemiology												
Sex (m/f)	5/3	10/14	n.s.	1/0	12/14	n.s.	2/3	4/2	n.s.	1/1	4/1	n.s.
Mean age, $y \pm SD$	9.7 \pm 5.0	11.2 \pm 3.8	n.s.	11.9*	9.1 \pm 4.0	n.s.	13.5 \pm 4.0	11.9 \pm 1.7	n.s.	13.5 \pm 0.6	9.2 \pm 3.2	n.s.
Mean duration of symptoms, mo $\pm SD$	1.4 \pm 1.0	2.0 \pm 2.7	n.s.	8.1*	1.9 \pm 2.0	0.008	1.6 \pm 1.4	3.7 \pm 4.8	n.s.	5.7*	0.6 \pm 0.4	=0.001
Histology												
Grading (II/III/IV)	–/6/2	–/9/15	n.s.	0/0/1	4/13/8 [#]	n.s.	–/1/4	–/3/3	n.s.	–/2/0	–/2/3	n.s.
p53 nuclear accumulation (yes/no)	2/5 [#]	14/5 [#]	n.s.	1/0	14/12	n.s.	1/2 [#]	1/2 [#]	n.s.	0/2	2/0 [#]	n.s.
Extent of resection												
Total/subtotal/partial/biopsy	0/1/3/4	0/3/13/8	n.s.	0/0/0/1	0/0/6/19 [#]	n.s.	1/1/1/2	2/2/1/1	n.s.	1/0/0/1	0/0/3/2	n.s.
Survival												
Event-free survival												
Median, y	1.98 \pm 1.83	0.13 \pm 0.19	0.008	1.52*	0.58 \pm 0.03	n.s.	0.93 \pm 2.4	0.49 \pm 0.15	n.s.	0.66	0.66 \pm 0.14	n.s.
After 1 y, %	57 \pm 19	21 \pm 8			17 \pm 8		50 \pm 25	20 \pm 18		50 \pm 35%	0	
After 2 y, %	43 \pm 19	0			4 \pm 4		50 \pm 25	0		50 \pm 35%	0	
Overall survival												
Median, y	3.85 \pm 1.03	1.11 \pm 0.14	0.002	2.37*	0.80 \pm 0.18	n.s.	6.1 \pm 0	0.40 \pm 0.68	0.005	–	0.68 \pm 0.06	n.s.
After 1 y, %	100	63 \pm 10			36 \pm 10		100	80 \pm 18		100	40 \pm 22	
After 2 y, %	71 \pm 17	13 \pm 7			11 \pm 7		75 \pm 22	0		100	0	

*Only one patient included, SD standard deviation, [#]missing values for some patients.

than those with H3.3 K27M-mutant tumors (5.9 \pm 4.1 y vs 10.6 \pm 3.5 y, respectively; $P = 0.007$).

Our series also included 8 very young (<3 y) children with diffuse midline gliomas. Their tumors included 2 DIPGs, 2 brainstem HGGs other than DIPG, and 4 spinal HGGs. All but 1 DIPG carrying an H3.1 K27M mutation were wildtype for H3 K27 (Supplementary Table S1).

Tumor Samples

Loss of nuclear expression of ATRX could be observed in 8 of 61 (13.1%) evaluable tumors, while 53/61 (86.9%) showed a retained ATRX expression in the tumor cell nuclei. No ATRX loss was found in 17 evaluable H3 K27-wildtype tumors, while 8 of 46 (17.4%) H3 K27M-mutant tumors lost nuclear ATRX expression, among them 1 of 6 (16.7%) H3.1 K27M-mutant tumors (not significant).

H3 K27M mutations were detected in 56 diffuse midline gliomas in *H3F3A* and in 6 gliomas in *HIST1H3B* (including 1 HGG from a patient <3 y of age). K27M-mutant gliomas were classified according to the fourth edition of the WHO classification of tumors of the CNS 2007² by central neuropathological review as glioblastoma grade IV ($n = 29$; 47%), anaplastic astrocytoma grade III ($n = 25$; 40%), diffuse astrocytoma grade II ($n = 4$; 6%), anaplastic ganglioglioma grade

III ($n = 1$), and diffuse astrocytomas without further grading ($n = 3$) due to small sample size. Tumor entities and histopathological grading did not differ significantly compared with their H3 K27-wildtype counterparts. Nuclear p53 accumulation was found in 62% of H3 K27M-mutant cases (31/50), but only in 31% (4/13) of H3 K27-wildtype tumors ($P = 0.044$). Accumulation of p53 did not differ significantly between tumors harboring either the H3.3 or the H3.1 K27M mutation.

Treatment

Treatment characteristics were similar between patients aged ≥ 3 years with H3 K27-wildtype and H3 K27M-mutant tumors. Most patients with H3 K27M-mutant gliomas underwent partial resection ($n = 23$) or non-debulking resection/biopsy ($n = 30$). Extent of resection did not differ significantly in H3-mutant and -wildtype tumors. In H3-mutant glioma, gross total or subtotal tumor resection was achieved in 7 patients. In H3 K27-wildtype gliomas, gross total resection or subtotal resection was achieved in 4/16 patients. Radiation was administered in 55/60 patients with H3 K27M-mutant tumors (92%) and in all 14 patients with H3 K27-wildtype gliomas (not significant). Chemotherapy was administered in 54/60 patients with H3 K27M-mutant tumors, comparable to the cohort with wildtype counterparts (15/15; not significant).

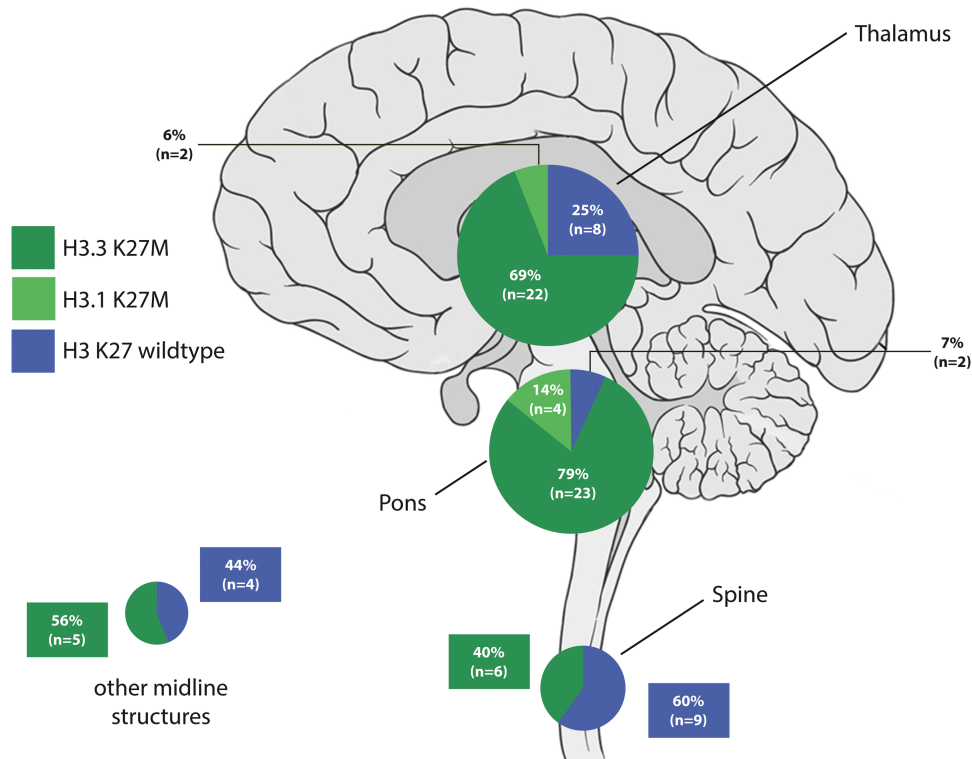


Fig. 1 Distribution of H3 K27 mutational status in 85 pediatric patients (including 8 children <3 y of age) with diffuse midline glioma.

Survival

For patients aged ≥ 3 years at diagnosis, median OS with H3 K27M-mutant midline glioma was 1.04 years (± 0.09 SE) compared with 6.1 years (± 2.0 SE) with H3 K27-wildtype tumors ($P < 0.001$; Fig. 2A). Survival for patients with H3 K27M-mutant tumors was still worse when restricting H3 K27-wildtype tumors to glioblastoma WHO grade IV ($P < 0.001$; Fig. 2B). Only 4/56 patients with H3.3 K27M-mutant gliomas and 1/5 patients with H3.1 K27M-mutant gliomas survived beyond 2 years after diagnosis. The poor impact on survival in H3 K27M-mutant glioma was also prevalent in thalamic and spinal gliomas compared with their wildtype counterparts ($P = 0.002$ and $P = 0.005$, respectively; Supplementary Figure S2), while H3 mutational status did not significantly affect survival in DIPG and gliomas from “other midline sites,” supposedly due to the small number of H3 K27-wildtype tumors in these locations (Table 1). However, survival with H3 K27M-mutant glioma was associated with an equally poor survival in all anatomic locations (Fig. 3). In our cohort, survival with H3.1 and H3.3 K27M mutation was comparable (median OS, 0.72 ± 0.18 y in H3.1 K27M DMGIV vs 1.1 ± 0.09 y in H3.3 K27M DMGIV; Supplementary Figure S3). Neuropathological tumor grading (eg, WHO grades III and IV) had no significant impact on survival in H3 K27M-mutant gliomas (Fig. 4) for the total cohort, nor did WHO grading affect survival when H3 K27M-mutant gliomas were restricted to the respective anatomic sites.

Risk Factors of Survival

Survival was not affected by extent of tumor resection in the entire cohort (Fig. 5A). In contrast, there was a trend toward improved survival in H3 K27-wildtype midline gliomas with extended resection $>90\%$ (Fig. 5B). Age < 3 years was a significant predictor of prolonged survival across the entire cohort of diffuse midline glioma ($P = 0.005$; Supplementary Figure S4A), as well as in a subset of H3 K27M-mutant glioma. However, the latter result is based on a single patient < 3 years of age affected by an H3.1 K27M-mutant tumor, which notably also harbored a *BRAF* V600E mutation (Supplementary Figure S5). When restricted to H3 K27-wildtype patients, survival in infants appeared similar to that in older patients (Supplementary Figure S4B). Multivariate analysis confirmed H3 K27M mutations as the only independent predictive parameter of OS ($P = 0.009$).

Discussion

Recent molecular studies have revolutionized our understanding of pediatric HGG, resulting in a new entity of “diffuse midline glioma, H3 K27M-mutant.”³ Since the discovery of histone 3 mutations in 2012,^{21,22} a limited number of histopathological tumor entities have been identified to carry H3 K27M mutations.^{23–27} However, potentially

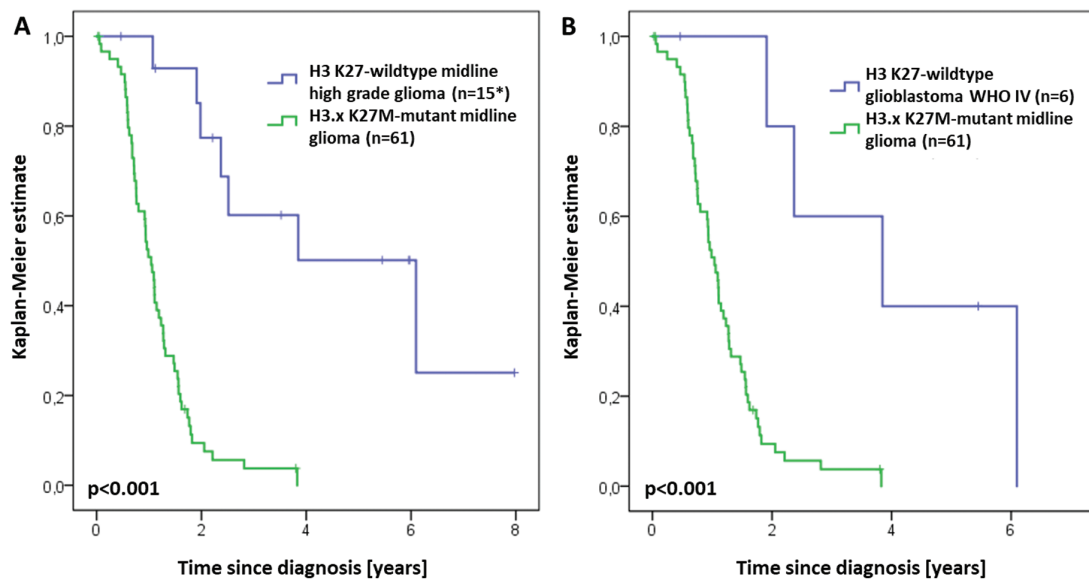


Fig. 2 (A) OS in 76 pediatric patients >3 y of age with diffuse midline gliomas, compared by H3 K27 mutational status (*survival data were missing for one patient). (B) OS comparing H3 K27M-mutant gliomas to only H3 K27-wildtype glioblastoma WHO grade IV.

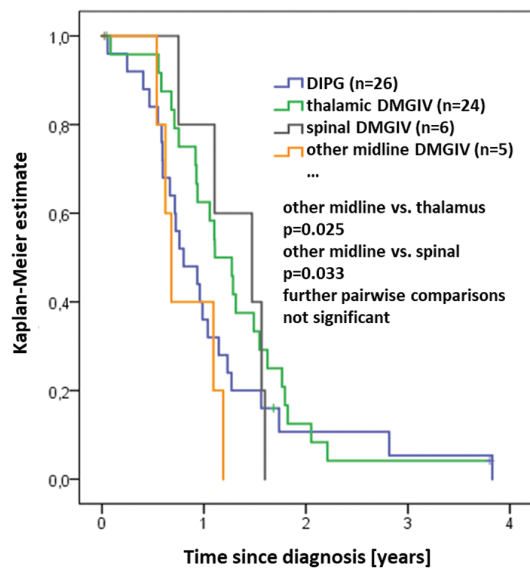


Fig. 3 OS in 61 patients >3 years of age at diagnosis with H3 K27M-mutant diffuse midline gliomas according to anatomic tumor location.

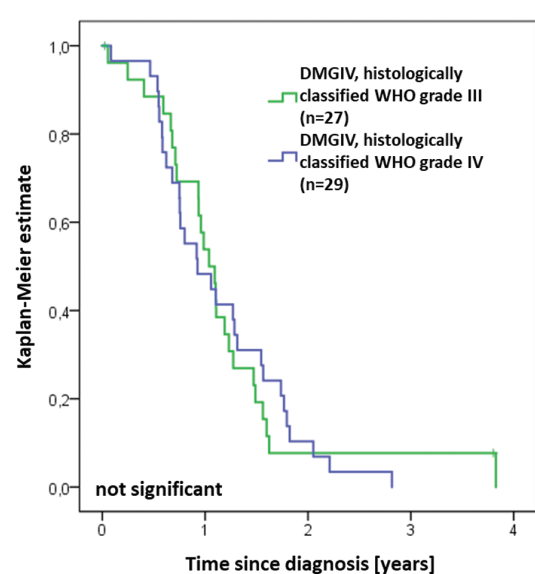


Fig. 4 OS in 56 patients with H3 K27M-mutant diffuse midline gliomas (DMGIV) according to histopathological tumor grading (eg, WHO grade III vs WHO grade IV).

reflecting a distinct cell of origin,²⁸ these tumors seem to exclusively evolve within midline structures of the CNS, with the highest prevalence in the pons.⁸

As expected, the biological behavior in our cohort of H3 K27M-mutant gliomas was dismal.^{10,29,30} In DIPG, H3 K27M mutations have been shown to be associated with worse survival compared with H3 K27-wildtype tumors.^{8,31} We

also demonstrate the prognostic significance of H3 K27M mutations in pediatric spinal and thalamic tumors, substantiating an insignificant trend observed in adult thalamic HGG. Prognosis was equally dismal in H3 K27M-mutant gliomas from all midline locations, while histology-based tumor grading did not have any prognostic impact on survival. Our findings corroborate the prognostic impact of H3

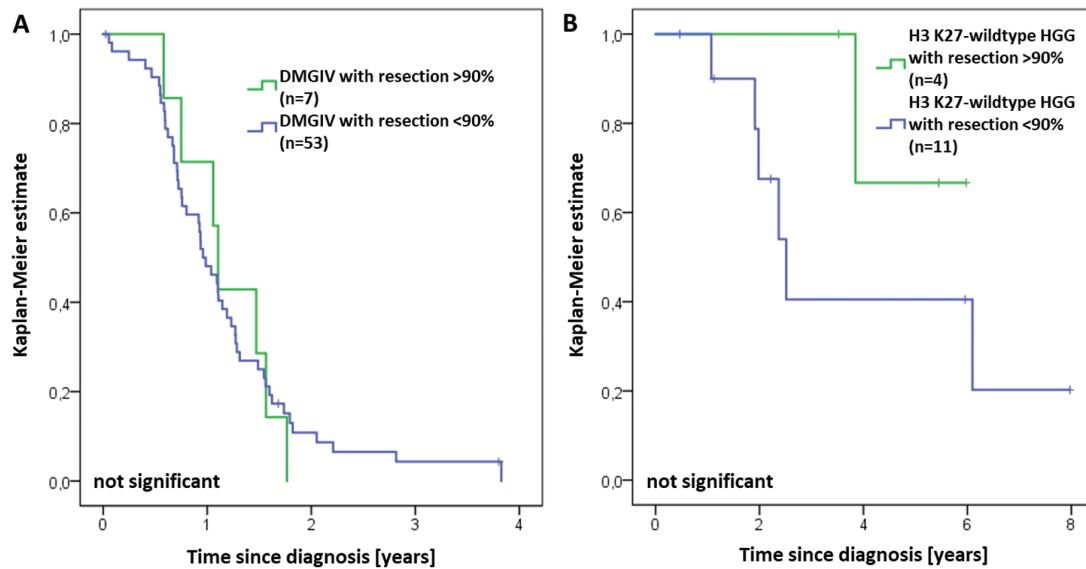


Fig. 5 (A) Extent of tumor resection was not associated with improved survival in H3 K27M-mutant midline glioma (DMGIV). (B) In contrast, there was a trend to an improved survival in H3 K27M-wildtype HGG with extended resection.

K27M mutations in diffuse midline gliomas and justify the definition of this entity as WHO grade IV tumors independent of histological grading.

The extent of tumor resection has been established as a strong predictor of survival in pediatric HGG.³² We could not substantiate this dogma in our cohort of H3 K27M-mutant gliomas, while Ryall and coworkers found extent of resection to be predictive of OS in thalamic glioma. Partly, this difference might be explained by the inclusion of a relevant number of low-grade gliomas that may account for a significant number of totally resected tumors.¹⁰ Further investigation is urgently warranted to substantiate or disprove our experience, but giving credit to the hypothesis that in DMGIV the clinical behavior may more closely follow molecular rather than known features of H3 wildtype pediatric HGG, future attempts for an extended tumor resection with a high risk of surgery-related morbidity should potentially be kept more restrictively in DMGIV than in other pediatric HGG.

Survival of both supratentorial HGG and DIPG patients is more favorable in very young children,^{33,34} substantiated in our cohort of diffuse midline glioma. However, there was no significant difference in survival between the 2 age groups when restricting our analysis to H3 K27M-wildtype tumors, supporting the hypothesis that superior survival in infants with diffuse midline gliomas may be due to the sparsity of H3 K27M mutations in that age group.^{8,19}

One infant DIPG classified as anaplastic astrocytoma WHO grade III harbored an H3.1 K27M mutation but was alive at the last follow-up 9 years from diagnosis (neuro-radiological imaging in Supplementary Figure S6). This tumor also harbored an additional *BRAF* V600E mutation, therefore being part of an emerging group of H3

K27M/*BRAF* V600E double mutant gliomas, which suggests biological overlap between histologically defined low- and high-grade gliomas and may be associated with longer-term survival irrespective of high-grade histology.^{23,24,35–37}

The results obtained from immunohistochemical analysis of ATRX expression are very close to previously reported data (eg, in the 2016 revised edition of the WHO classification, 15% of diffuse midline glioma, H3 K27M-mutant are stated with ATRX loss).³ Interestingly, no ATRX loss was found in 17 evaluable H3 K27M-wildtype tumors, maybe due to the relatively small number of patients. However, in non-midline, H3 K27M-wildtype infant HGG previously published,¹⁹ 17.1% of the tumors showed loss of ATRX expression, again in the same frequency shown here for H3 K27M-mutant tumors. Also in the cohort reported here, there is no evidence for a significant statistical correlation between histone mutational status and loss of nuclear ATRX expression.

The results of the present study extend our current knowledge about the phenotypic spectrum of diffuse midline gliomas in children. The prevalence of H3.3 K27M mutations was highest in tumor in the pons, followed by thalamus and spine, in line with previous series.^{26,38} A minority of tumors harbored H3.1 K27M mutations as reported previously^{8,12} but were not restricted to the pons in our series,^{1,12} underlining earlier observed clinical similarities between thalamic HGG and DIPG in children.³⁹

Nuclear accumulation of p53 was prevalent in the majority of H3 K27M-mutant midline gliomas, with either H3.3 or H3.1 mutations,^{3,38} and less frequent in H3 wildtype glioma.¹⁹ These findings are in line with previously reported data⁴⁰ supporting the observation that alterations of the p53 pathway are more common in H3 K27M-mutant gliomas than in their H3 K27M-wildtype counterparts.

In conclusion, K27M-mutant diffuse midline gliomas resemble their H3 K27-wildtype counterparts regarding epidemiologic features but are associated with a significantly worse survival across all midline tumor locations. As extended tumor resection does not seem to provide a prognostic benefit, substantial basic research and development of sustainable therapeutic concepts are urgently needed.

Supplementary material

Supplementary material is available at *Neuro-Oncology* online.

Funding

This work was supported by Deutsche Kinderkrebsstiftung (grant no. DKS2016.13 to C.M.K. for the HIT-HGG database; grant no. DKS2014.17 to T.P. for central neuropathological review; and grant no. DKS2014.15 to M.W.-M. for central neuroradiological review) and the Styrian Childhood Cancer Foundation supporting the Austrian HIT-HGG study center.

Acknowledgments

We appreciate the ongoing support of the Deutsche Kinderkrebsstiftung, Bonn, Germany for the German pediatric brain tumor (HIT) network. The Austrian HIT-HGG study center is supported by the Styrian Childhood Cancer Foundation. The authors want to thank PD Dr Christian Riedel, Department of Radiology and Neuroradiology, Schleswig-Holstein Medical University in Kiel, Germany for providing neuroradiological imaging (Supplementary Figure S6). We also thank all colleagues who contributed patients and their data to the HIT-GBM/HIT-HGG studies.

Conflict of interest statement. The authors report no conflict of interest.

References

- Jones C, Karajannis MA, Jones DTW, et al. Pediatric high-grade glioma: biologically and clinically in need of new thinking. *Neuro Oncol.* 2017;19(2):153–161.
- Louis DN, Ohgaki H, Wiestler B, Cavanee WK. *WHO Classification of Tumours of the Central Nervous System.* 4th ed. Lyon: IARC Press; 2007.
- Hawkins C, Ellison DW, Sturm D. Diffuse midline glioma, H3 K27M-mutant. In: Louis DN, Ohgaki H, Wiestler OD, et al, eds. *WHO Classification of Tumours of the Central Nervous System.* Rev. 4th ed. Lyon: IARC Press; 2016:57–59.
- Bender S, Tang Y, Lindroth AM, et al. Reduced H3K27me3 and DNA hypomethylation are major drivers of gene expression in K27M mutant pediatric high-grade gliomas. *Cancer Cell.* 2013;24(5):660–672.
- Lewis PW, Müller MM, Koletsy MS, et al. Inhibition of PRC2 activity by a gain-of-function H3 mutation found in pediatric glioblastoma. *Science.* 2013;340(6134):857–861.
- Chan KM, Fang D, Gan H, et al. The histone H3.3K27M mutation in pediatric glioma reprograms H3K27 methylation and gene expression. *Genes Dev.* 2013;27(9):985–990.
- Fontebasso AM, Liu XY, Sturm D, Jabado N. Chromatin remodeling defects in pediatric and young adult glioblastoma: a tale of a variant histone 3 tail. *Brain Pathol.* 2013;23(2):210–216.
- Khuong-Quang DA, Buczkowicz P, Rakopoulos P, et al. K27M mutation in histone H3.3 defines clinically and biologically distinct subgroups of pediatric diffuse intrinsic pontine gliomas. *Acta Neuropathol.* 2012;124(3):439–447.
- Aihara K, Mukasa A, Gotoh K, et al. H3F3A K27M mutations in thalamic gliomas from young adult patients. *Neuro Oncol.* 2014;16(1):140–146.
- Ryall S, Krishnaty R, Arnold A, et al. Targeted detection of genetic alterations reveal the prognostic impact of H3K27M and MAPK pathway aberrations in paediatric thalamic glioma. *Acta Neuropathol Commun.* 2016;4(1):93.
- Feng J, Hao S, Pan C, et al. The H3.3 K27M mutation results in a poorer prognosis in brainstem gliomas than thalamic gliomas in adults. *Hum Pathol.* 2015;46(11):1626–1632.
- Castel D, Philippe C, Calmon R, et al. Histone H3F3A and HIST1H3B K27M mutations define two subgroups of diffuse intrinsic pontine gliomas with different prognosis and phenotypes. *Acta Neuropathol.* 2015;130(6):815–827.
- Wolff JE, Driever PH, Erdlenbruch B, et al. Intensive chemotherapy improves survival in pediatric high-grade glioma after gross total resection: results of the HIT-GBM-C protocol. *Cancer.* 2010;116(3):705–712.
- Wolff JE, Kortmann RD, Wolff B, et al. High dose methotrexate for pediatric high grade glioma: results of the HIT-GBM-D pilot study. *J Neurooncol.* 2011;102(3):433–442.
- Wolff JE, Mölenkamp G, Westphal S, et al. Oral trofosfamide and etoposide in pediatric patients with glioblastoma multiforme. *Cancer.* 2000;89(10):2131–2137.
- Wolff JE, Wagner S, Reinert C, et al. Maintenance treatment with interferon-gamma and low-dose cyclophosphamide for pediatric high-grade glioma. *J Neurooncol.* 2006;79(3):315–321.
- Rutkowski S, Bode U, Deinlein F, et al. Treatment of early childhood medulloblastoma by postoperative chemotherapy alone. *N Engl J Med.* 2005;352(10):978–986.
- Karremann M, Rausche U, Roth D, et al. Cerebellar location may predict an unfavourable prognosis in paediatric high-grade glioma. *Br J Cancer.* 2013;109(4):844–851.
- Gielen GH, Gessi M, Buttarelli FR, et al. Genetic analysis of diffuse high-grade astrocytomas in infancy defines a novel molecular entity. *Brain Pathol.* 2015;25(4):409–417.
- Takami H, Yoshida A, Fukushima S, et al. Revisiting TP53 mutations and immunohistochemistry—a comparative study in 157 diffuse gliomas. *Brain Pathol.* 2015;25(3):256–265.
- Schwartzentruber J, Korshunov A, Liu XY, et al. Driver mutations in histone H3.3 and chromatin remodelling genes in paediatric glioblastoma. *Nature.* 2012;482(7384):226–231.
- Wu G, Broniscer A, McEachron TA, et al; St Jude Children's Research Hospital–Washington University Pediatric Cancer Genome Project. Somatic histone H3 alterations in pediatric diffuse intrinsic pontine gliomas and non-brainstem glioblastomas. *Nat Genet.* 2012;44(3):251–253.
- Jones DT, Hutter B, Jäger N, et al; International Cancer Genome Consortium PedBrain Tumor Project. Recurrent somatic alterations of FGFR1 and NTRK2 in pilocytic astrocytoma. *Nat Genet.* 2013;45(8):927–932.
- Zhang J, Wu G, Miller CP, et al; St Jude Children's Research Hospital–Washington University Pediatric Cancer Genome Project. Whole-genome

- sequencing identifies genetic alterations in pediatric low-grade gliomas. *Nat Genet.* 2013;45(6):602–612.
25. Gessi M, Capper D, Sahn F, et al. Evidence of H3 K27M mutations in posterior fossa ependymomas. *Acta Neuropathol.* 2016;132(4):635–637.
 26. Gessi M, Gielen GH, Dreschmann V, Waha A, Pietsch T. High frequency of H3F3A (K27M) mutations characterizes pediatric and adult high-grade gliomas of the spinal cord. *Acta Neuropathol.* 2015;130(3):435–437.
 27. Gielen GH, Gessi M, Hammes J, Kramm CM, Waha A, Pietsch T. H3F3A K27M mutation in pediatric CNS tumors: a marker for diffuse high-grade astrocytomas. *Am J Clin Pathol.* 2013;139(3):345–349.
 28. Jones C, Baker SJ. Unique genetic and epigenetic mechanisms driving paediatric diffuse high-grade glioma. *Nat Rev Cancer.* 2014;14(10):doi:10.1038/nrc3811.
 29. Korshunov A, Ryzhova M, Hovestadt V, et al. Integrated analysis of pediatric glioblastoma reveals a subset of biologically favorable tumors with associated molecular prognostic markers. *Acta Neuropathol.* 2015;129(5):669–678.
 30. Sturm D, Witt H, Hovestadt V, et al. Hotspot mutations in H3F3A and IDH1 define distinct epigenetic and biological subgroups of glioblastoma. *Cancer Cell.* 2012;22(4):425–437.
 31. Buczkowicz P, Bartels U, Bouffet E, Becher O, Hawkins C. Histopathological spectrum of paediatric diffuse intrinsic pontine glioma: diagnostic and therapeutic implications. *Acta Neuropathol.* 2014;128(4):573–581.
 32. Kramm CM, Wagner S, Van Gool S, et al. Improved survival after gross total resection of malignant gliomas in pediatric patients from the HIT-GBM studies. *Anticancer Res.* 2006;26(5B):3773–3779.
 33. Duffner PK, Krischer JP, Burger PC, et al. Treatment of infants with malignant gliomas: the Pediatric Oncology Group experience. *J Neurooncol.* 1996;28(2–3):245–256.
 34. Broniscer A, Laningham FH, Sanders RP, Kun LE, Ellison DW, Gajjar A. Young age may predict a better outcome for children with diffuse pontine glioma. *Cancer.* 2008;113(3):566–572.
 35. Pages M, Beccaria K, Boddaert N, et al. Co-occurrence of histone H3 K27M and BRAF V600E mutations in paediatric midline grade I ganglioglioma. *Brain Pathol.* 2016. doi: 10.1111/bpa.12473.
 36. Mistry M, Zhukova N, Merico D, et al. BRAF mutation and CDKN2A deletion define a clinically distinct subgroup of childhood secondary high-grade glioma. *J Clin Oncol.* 2015;33(9):1015–1022.
 37. Nguyen AT, Colin C, Nanni-Metellus I, et al; French GENOP Network. Evidence for BRAF V600E and H3F3A K27M double mutations in paediatric glial and glioneuronal tumours. *Neuropathol Appl Neurobiol.* 2015;41(3):403–408.
 38. Solomon DA, Wood MD, Tihan T, et al. Diffuse midline gliomas with histone H3-K27M mutation: a series of 47 cases assessing the spectrum of morphologic variation and associated genetic alterations. *Brain Pathol.* 2016;26(5):569–580.
 39. Kramm CM, Butenhoff S, Rausche U, et al. Thalamic high-grade gliomas in children: a distinct clinical subset? *Neuro Oncol.* 2011;13(6):680–689.
 40. Pollack IF, Finkelstein SD, Burnham J, et al; Children's Cancer Group. Age and TP53 mutation frequency in childhood malignant gliomas: results in a multi-institutional cohort. *Cancer Res.* 2001;61(20):7404–7407.